

LIPOSUCTION AS A TREATMENT FOR LYMPHOEDEMA

Dr Håkan Brorson, Dr Carolin Freccero




Figure 1: Olof Rudbeck, 1630–1702

In the 1700s, Olof Rudbeck from Uppsala, Sweden (Figure 1) outlined the function of the lymphatics. In 1653 he wrote a thesis about the lymphatic system (Figure 2). Figure 3 shows a diagram of the liver and the lymph vessels entering the cisterna chyli and finally, via the thoracic duct, emptying into the venous junctions in the neck. In the 1700s scientists thought that the lymph vessels drained to the liver. In 1652, Olof Rudbeck performed an autopsy to show that the lymphatic vessels instead drained the liver and bowels as well as the legs (Figure 3). Thomas Bartholin from Denmark (Figure 4) was told about these findings and was fascinated by this procedure and likewise started to do dissections. In 1653, Bartholin presented his thesis four weeks before Rudbeck's, resulting in one of the great academic disputes of the 1700s.




Figure 2: Rudbeck thesis — *Novo exercitatio anatomica, exhibens ductus hepaticos aquosus et vasa glandularum serosa*

Figure 5 shows a patient in the 1960s after surgery for breast cancer, suffering the effects of heavy irradiation. She had disturbances of both the lymph and blood circulation and had to undergo amputation. Fortunately today, patients do not undergo such high levels of radiation, but rather more frequent, low-level radiation that causes less damage.

Figures 6 and 7 show typical patients who have presented at the authors' clinic in Malmö, Sweden. The literature shows that there have been a number of surgical techniques for lymphoedema (Figure 8). Figure 9 shows two patients with bilateral lymphoedema who were operated on in the 1960s. They were treated by excision of the skin and subcutaneous tissue down to the muscle fascia, which was covered with split skin grafts (Charles' procedure). In contrast to liposuction, this technique resulted in poor cosmetic outcomes and patients often had problems with subsequent scarring, eczema, lymph fistulas, etc. The authors have not performed this procedure for the last 15 years.

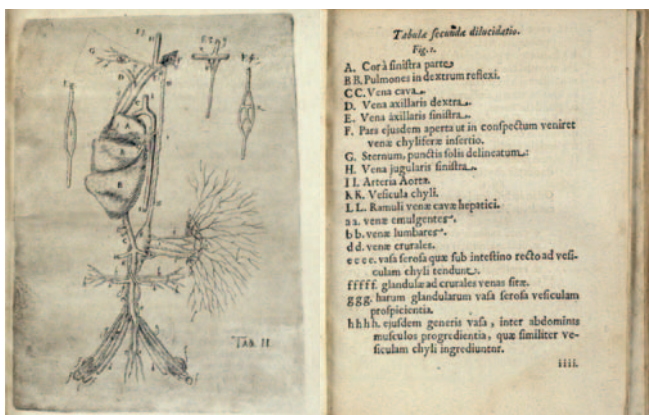

Figure 3: *Novo exercitatio anatomica*



Figure 4: Thomas Bartholin, 1616–1680

In 1998, the first author wrote a thesis entitled *Liposuction and controlled compression therapy in the treatment of arm lymphoedema following breast cancer* (Brorson, 1998), which further increased the interest and knowledge in liposuction as a treatment for lymphoedema. This thesis included five different papers on how to treat lymphoedema with liposuction. The first paper explored how complete reduction of lymphoedema could be gained (Brorson and Svensson, 1997a), and another described a randomised trial where liposuction and compression were used, versus compression alone (Brorson and Svensson, 1998). The compression-only group achieved a 47% reduction of excess volume in the lymphoedema, but the group with surgery as well showed complete reduction (100% reduction). In those early days, the pitting test was not performed as rigorously as it is done today, thus explaining the effect of compression, which mobilises fluid but not fat.

In one paper, the author showed that liposuction did not further reduce an already decreased lymph transport system. This was important because some clinicians thought that the lymphatics were destroyed by the procedure (Brorson et al, 1998).

Another paper found that skin blood flow increased after surgery, which possibly explained why patients had fewer attacks of erysipelas after surgery (Brorson and Svensson, 1997b). The last paper dealt with the improvement of quality of life found after surgery (Brorson et al, 2006a).

Pitting test

The pitting test is a quick and easy method of deciding which patients are suitable for surgery. 'Pitting' refers to the depression formed after pressure is applied to the oedematous tissue. The thumb presses as hard as possible on the extremity to be investigated for 60 seconds, the amount of depression being estimated in millimetres (Figure 10a). Oedema that is mainly hypertrophied adipose tissue and/or fibrosis shows little or no pitting (Figure 10b).

In 1993, a magnetic resonance imaging scan (MRI) was taken of the first patient to undergo liposuction. On analysis, excess adipose tissue could be seen (Figure 13). Figure 11 shows a picture of excess fat volume in the lymphoedematous arm taken in the 1960s. The authors had often been told that the excess volume was dominated by fibrosis. Fat was never spoken of. Thus, the liposuction aspirate in patients was analysed and 90–100% fat was found. If it had simply been fluid, it would have been 90% fluid and maybe 10% fat. Figure 12 shows the aspirate, from a typical patient, in a 2-litre canister. The adipose tissue separates into an upper adipose fraction (90%) and a lower fluid (lymph) fraction (10%).

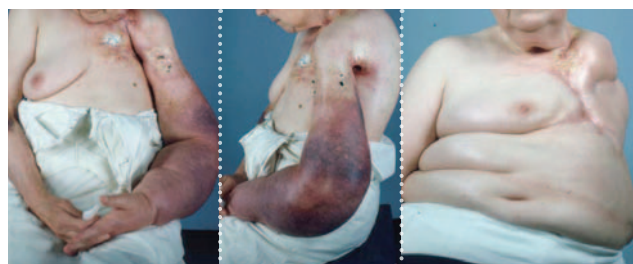

Figure 5: Patient suffering the effects of heavy irradiation in the 1960s who had to undergo amputation



Figure 6: Patient with excess volume of 2.1 litres

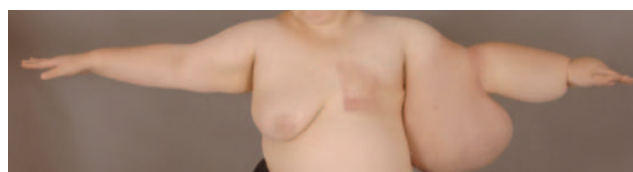

Figure 7: Patient with excess of volume 12.3 litres

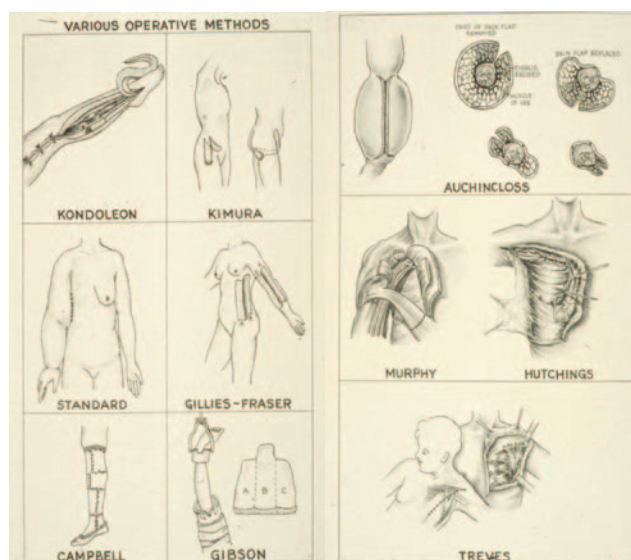


Figure 8: Examples of various operative techniques

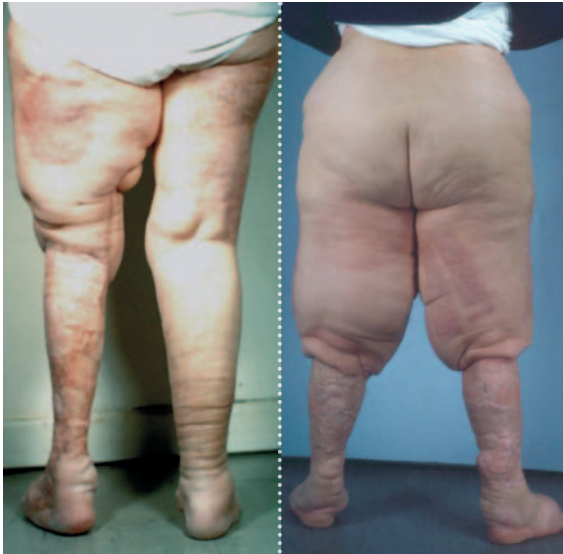

Figure 9: Typical results after excision of skin and subcutaneous tissue followed by split skin grafting

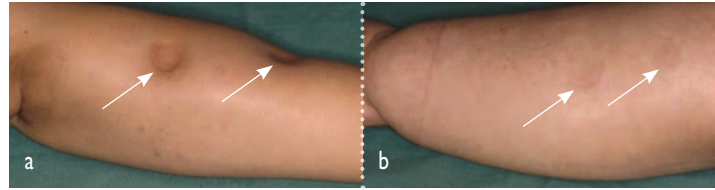


Figure 10a. Marked lymphoedema of the arm after breast cancer treatment, showing pitting several centimetres in depth. The arm swelling is dominated by the presence of fluid, i.e. the accumulation of lymph. Figure 10b. Pronounced arm lymphoedema after breast cancer treatment. There is no pitting in spite of hard pressure by the thumb for one minute. A slight reddening is seen at the two spots where pressure has been exerted. The 'oedema' is completely dominated by adipose tissue. The term 'oedema' is improper at this stage since the swelling is dominated by hypertrophied adipose tissue and not by lymph. At this stage, the aspirate contains either no, or a minimal amount of lymph

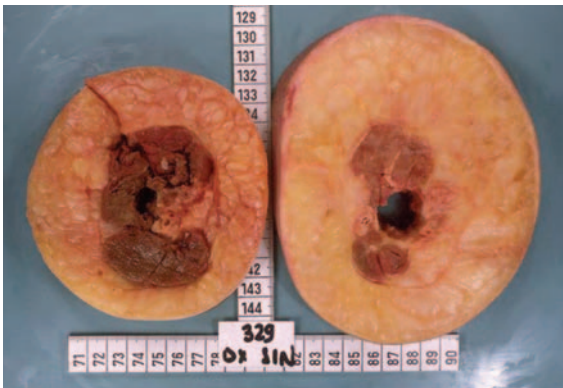


Figure 11: Cross-sections of a lymphoedematous (right) and a normal arm (left) showing abundance of excess adipose tissue in the affected arm



Figure 12: The aspirate contains 90–100% adipose tissue in general

Evidence of adipose tissue in lymphoedema

Indications for adipose tissue hypertrophy include:

- Consecutive analyses of the content of the aspirate removed under bloodless conditions using a tourniquet showed that a high content of adipose tissue in 44 women with postmastectomy arm lymphoedema (mean 90%, range 58–100) was found (Brorson et al, 2004)
- Analyses with dual X-ray absorptiometry (DXA) in 18 women with arm lymphoedema following breast cancer treatment showed a 73% increase in volume of adipose tissue in the non-pitting swollen arm before surgery (Brorson et al, 2009)
- Preoperative investigation with volume rendered computer tomography (VR-CT) images in eight patients, following breast cancer treatment, showed a significant preoperative increase of adipose tissue in the swollen arm, the excess volume consisting of 81% fat (Brorson et al, 2006a)
- Tonometry findings in 20 women with postmastectomy arm lymphoedema showed postoperative changes in the upper arm, but not in the forearm, which also showed significantly higher absolute values than in the upper arm. This is probably caused by the high adipose tissue content with little or no free fluid, just like the situation in the normal arm. The thinner subcutaneous tissue in the forearm may also play a part. Tonometry can

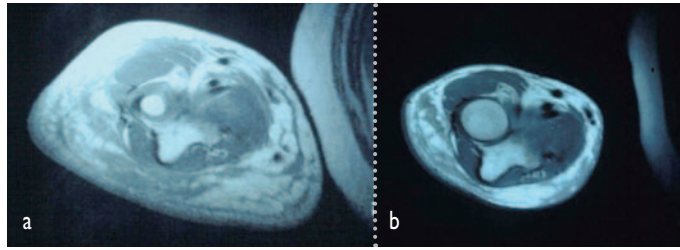


Figure 13a: Preoperative. Figure 13b: One year postoperatively

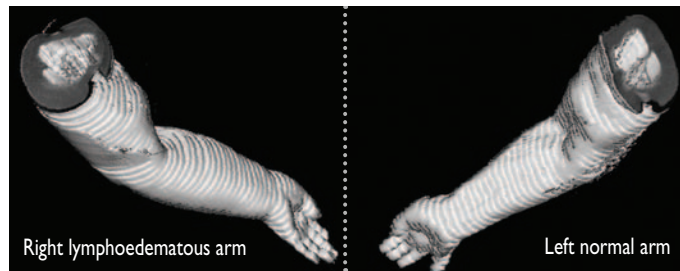


Figure 14: Volume rendering computer tomography (VR-CT) images showing 1.3 litres of excess fat in the right arm

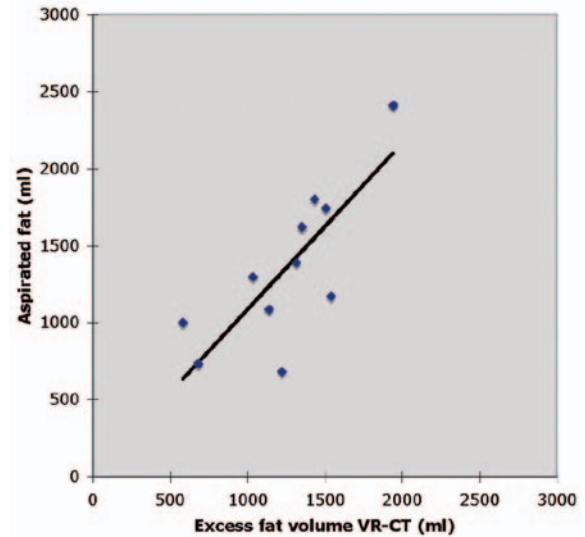


Figure 15: Aspirated fat versus VR-CT excess fat volume. Reproduced by kind permission of Lymphatic Research and Biology (Brorson et al, 2006b)

distinguish if a lymphoedematous arm is harder or softer than the normal one. If a lower tissue tonic value is recorded in the oedematous arm, it indicates that there is accumulated lymph fluid in the tissue, and these patients are candidates for conservative treatment. In contrast, patients with a harder arm compared with the healthy one, have an adipose tissue excess that can successfully be removed by liposuction (Bagheri et al, 2005)

- The findings of increased adipose tissue in intestinal segments in patients with Crohn's disease, known as 'fat wrapping', have clearly shown that inflammation plays an important role (Jones et al, 1986; Sheehan et al, 1992; Borley et al, 2000)
- In Graves' ophthalmopathy, a major problem is an increase in the intraorbital adipose tissue volume leading to exophthalmus. Adipocyte related immediate early genes (IEGs) are overexpressed in active ophthalmopathy and cysteine-rich, angiogenic inducer 61 (CYR61) may have a role in both orbital inflammation and adipogenesis and serve as a marker of disease activity (Lantz et al, 2005).

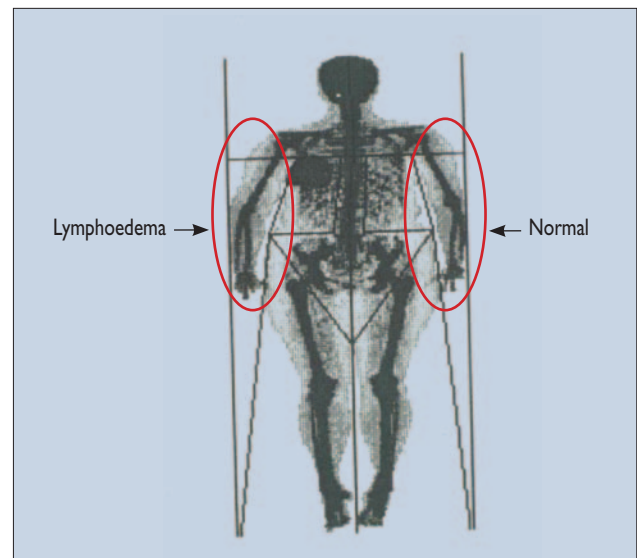


Figure 16: Dual energy X-ray absorptiometry (DXA)

Measurement techniques

In the authors' opinion, the problem with non-pitting lymphoedema is fat, not lymph. Looking at an MRI scan before and after surgery, there is a considerable reduction of the excess volume (Figures 13a, b). However, to achieve objective measurements further analysis with VR-CT can be performed. This involves tomography of both arms with the computer being programmed only to show pixels for fat. Fat volume can be calculated by measuring the fat pixels.

Figure 14 shows a patient with an excess fat volume of 1.3 litres. This is an objective sign of excess adipose tissue. The amount of aspirated fat can also be correlated to the excess fat volume measured with computer tomography (Figure 15).

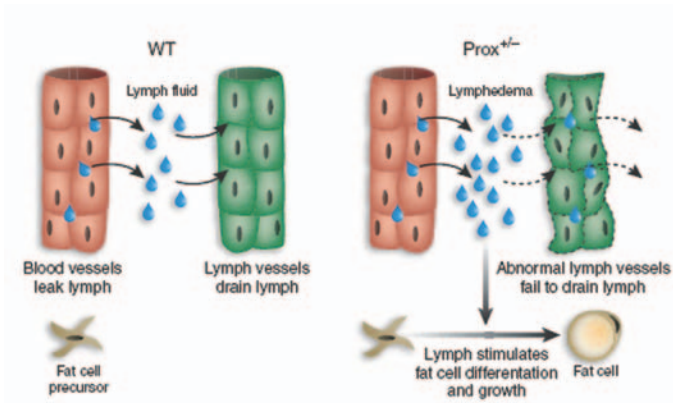


Figure 17 Lymph makes you fat. Reprinted by permission from *Nature Genetics*, October, 2005 (Schneider et al, 2005)

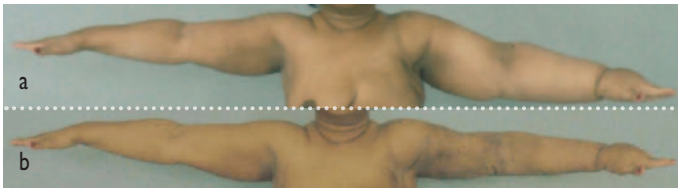


Figure 18a: Preoperatively, 2.315 ml; Figure 18b: four weeks postoperatively

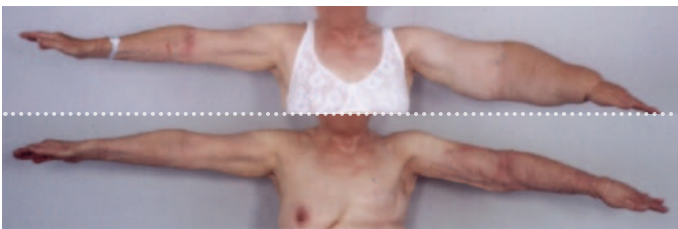

Figure 19a: A 74-year-old woman with a non-pitting arm lymphoedema for 15 years. Preoperative excess volume was 3.1 litres. Figure 19b: One year postoperatively

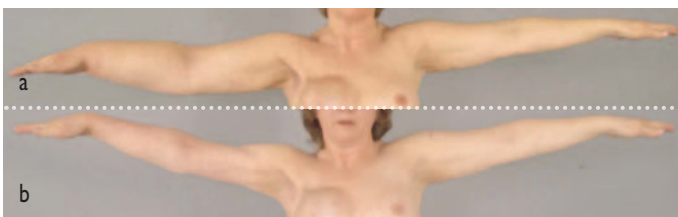


Figure 20a: Preoperatively, 1.335 ml; Figure 20b: One year postoperatively

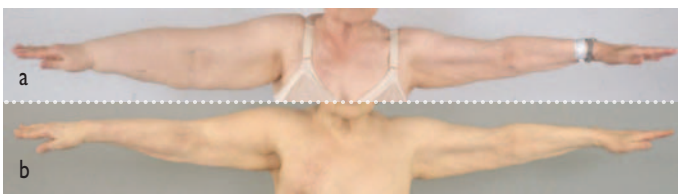


Figure 21a: Preoperatively, 2.480 ml; Figure 21b: Five years postoperatively

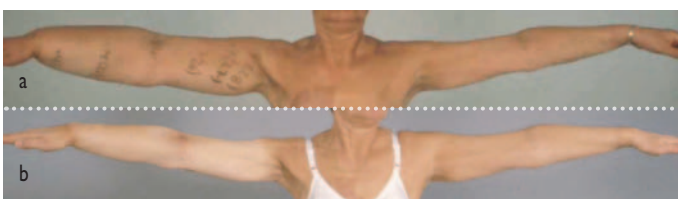


Figure 22a: Preoperatively, 2.200 ml; Figure 22b: 14 years postoperatively

Another measurement technique is DXA, where fat, muscle and bone are measured in grams and transferred to volumes by density. Figure 16 shows a typical patient where DXA shows an excess of 510 grams in the lymphoedematous arm. The same relationship with aspirated fat and excess fat volume measured with VR-CT was found. The amount of excess adipose tissue in the lymphoedematous arm showed a mean excess amount of fat of 73% using DXA (Brorson et al, 2009), and of 81% using VR-CT (Brorson et al, 2006b).

Both VT-CT and DXA are methods to objectively show excess adipose tissue merely for research purposes. This is not necessary in the clinical situation where the pitting test is sufficient.

In 2005, Harvey et al cited in *Nature Genetics* one of the authors' earlier works regarding findings of excess adipose tissue (Harvey et al, 2005). Figure 17 shows that in the wild type (WT) mouse fluid leaks from blood capillaries and is collected by the lymph vessels and is transported back to the blood circulation (left-hand image). In the Prox^{1+/-} mice, impaired lymph drainage caused accumulation of lymph fluid in the tissues, where it induced excess differentiation of fat cell precursors and fat cell hypertrophy (right-hand image). The factors determining the adipogenic potency of lymph are not known (Schneider et al, 2005).

Inflammation is probably one of the causes of excess fat deposition. The goal of liposuction should be to remove excess fat and achieve complete reduction. Figures 18–22 show some typical results.

Initially, liposuction was done as a 'dry' technique, no dilute adrenaline or anaesthetics being injected into the adipose tissue beforehand (Clayton et al, 1989). A disadvantage of the 'dry' technique was the large amount of blood lost (Courtiss et al, 1992). Most surgeons recommended that no more than 1500ml of fat should be removed to avoid the need for blood transfusions.

Illouz was the first to infiltrate the subcutaneous fatty tissue when doing liposuction (Illouz, 1983). In the early 1980s most surgeons used the 'wet' technique (Goodpasture and Bunkis, 1986), which involves infiltration of 200–300ml of

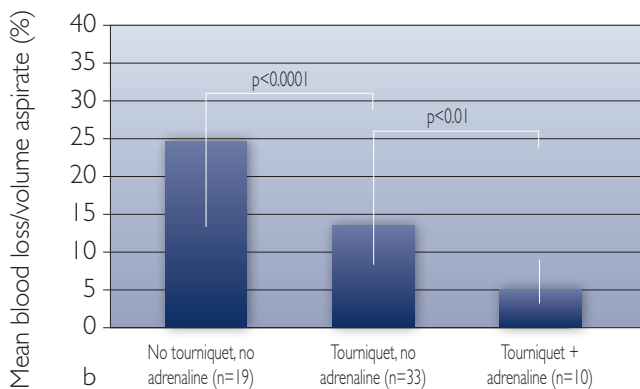


Figure 23: Mean blood loss (ml) in the groups with lymphoedema. Reproduced by kind permission of the Scandinavian Journal of Plastic Reconstructive Surgery and Hand Surgery (Wojnikow et al, 2007). Available online at: www.informaworld.com/sjplastic

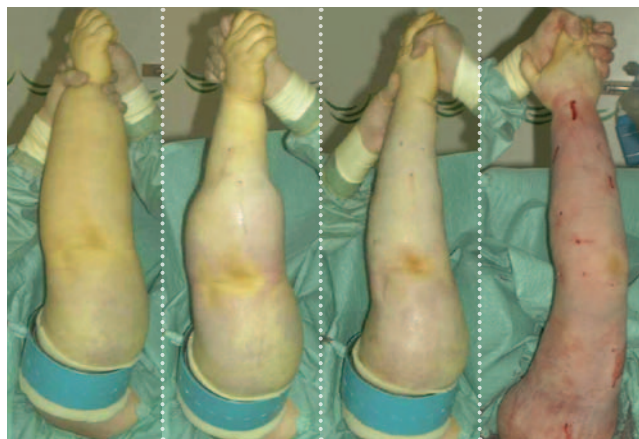


Figure 24: Liposuction of arm lymphoedema. The procedure takes about two hours. From preoperative to postoperative state (left to right). Note the tourniquet, which has been removed at the right, and the concomitant reactive hyperaemia

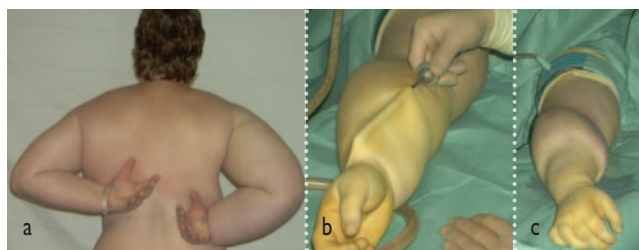


Figure 25a: Preoperative picture showing a patient with a large lymphoedema (2.900 ml) and decreased mobility of the right arm. Figure 25b: The cannula lifts the loose skin of the treated forearm. Figure 25c: The distal half of the forearm has been treated. Note the sharp border between treated (distal forearm) and untreated (proximal arm) area

normal saline with or without lignocaine, adrenaline, or a combination, into the surgical area before liposuction.

In 1986 the 'superwet' technique was introduced, which involves infiltration of a solution of normal saline containing adrenaline and lignocaine in an amount equal to that of the fat that is to be removed (Rohrich and Mathes, 1990).

The following year, Klein described the 'tumescent' technique, which involves somewhat larger amounts of saline containing both low-dose adrenaline and lignocaine in a ratio of 2–3:1 ml (infiltrate:aspirate) being injected (Klein, 1987).

These techniques enabled surgeons to remove large quantities of adipose tissue. By infiltrating dilute adrenaline and lignocaine into subcutaneous fat, both the excessive loss of blood and the need for general anaesthesia with its associated risks are reduced (Wojnikow et al, 2007).

According to other authors, more than 3000ml of fat can be removed during liposuction under local anaesthesia without sedation (Klein, 1987; Klein, 1993). Samdal et al (1995) reported the amount of whole blood contained in the aspirate is roughly 2% (volume/volume) when superwet or tumescent techniques are used, whereas in the 'dry' technique it is 25% (Goodpasture and Bunkis, 1986), and in the wet technique 15% (Clayton et al, 1989).

When the authors' team started to treat arm lymphoedema following breast cancer treatment, they used the 'dry technique'. Later, to minimise blood loss, a tourniquet was used in combination with tumescence. Liposuction was performed up to the distal edge of the tourniquet. A sterile compression garment was put on and the tourniquet released. The area covered by the tourniquet was infiltrated with dilute adrenaline before liposuction was completed (tumescence) (Figure 23; Wojnikow et al, 2007). This technique keeps blood loss to a minimum, thus removing the need for transfusions.

How to perform liposuction for lymphoedema — surgical technique

Liposuction for both leg and arm lymphoedema is similar; removing excess hypertrophied adipose tissue under bloodless conditions (Figure 24). General




Figure 26: Cannulas: The upper cannula is used for aesthetic procedures, whereas the lower is used for liposuction for lymphoedema. Note the larger openings at the tip

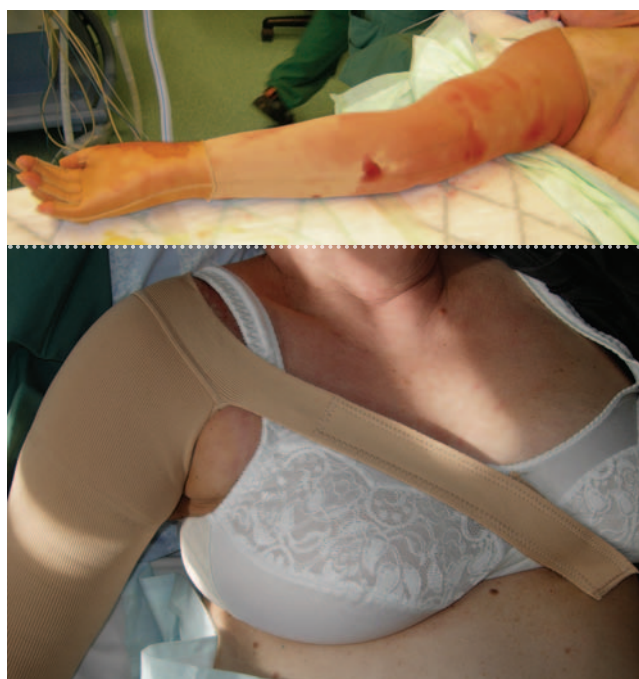

Figure 27: After liposuction on the proximal part of the upper arm the garment is pulled up and secured with the bands of the garments that are fastened with velcro

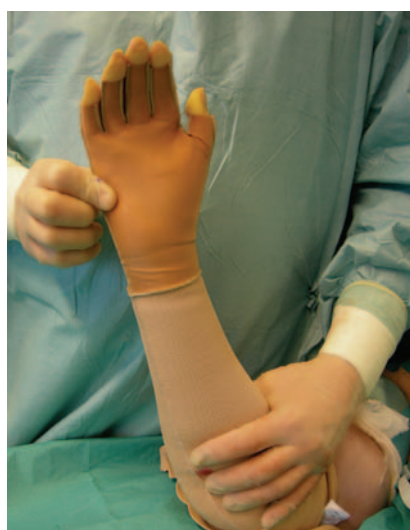

Figure 28: Glove with fingertips cut off

anaesthesia is used in most cases but some patients with arm lymphoedema prefer nerve blockade with a plexus and scalenus block. Neither local anaesthetic nor epinephrine is injected distal to the tourniquet; hence, the 'dry technique' is used. Through around 15–20, 3mm long incisions, the shoulder and arm are treated (Figures 24 and 25).

Cannulas are connected to a vacuum pump giving a negative atmospheric pressure of 0.9. The cannulas are 15 cm long with an outer diameter of 3 and 4 mm, with three openings at the tip (Figure 26). The finer cannula is used mainly for the distal part of the forearm, and also when irregularities are remedied. The openings differ from normal liposuction cannulas in that they take up almost half of the circumference to facilitate the liposuction, especially in lymphoedemas with excess fibrosis. Liposuction of an arm can be done manually using ordinary cannulas (Figure 26) or by power assisted liposuction, which uses a vibrating cannula to facilitate and speed up surgery. This is especially important in the leg.

Made-to-measure compression garments (two sleeves and two gloves) are ordered two weeks before surgery. The size of the garments is measured according to the size of the healthy arm and hand. Liposuction is executed circumferentially, step-by-step, from hand to shoulder, and the hypertrophied fat is removed as completely as possible (Figure 24).

When the arm distal to the tourniquet has been treated, a sterilised made-to-measure compression sleeve is applied (Jobst® Elvarex BSN medical, compression class 2) on the arm to stem bleeding and postoperative oedema (Figure 27). An Elasto-Gel (Southwest Technologies, USA), 10x10cm, is put on the ventral aspect of the elbow joint (for the first two weeks), and between the thumb and index finger to ease off the pressure from the new garment and glove. A sterilised Easy-Slide (Credenhill, England) facilitates putting on the garment and is later always used for this procedure. A sterilised, standard interim glove (Cicatrex interim, Thuasne®, France), where the tips of the fingers have been cut to facilitate gripping, is put on the hand (Figure 28). The tourniquet is removed and the most proximal part of the upper arm is treated using the tumescent technique. Finally, the proximal part of the compression sleeve is pulled up to compress the proximal part of the upper arm. The incisions are left open to drain through the sleeve. The arm is lightly wrapped with a large absorbent compress covering the

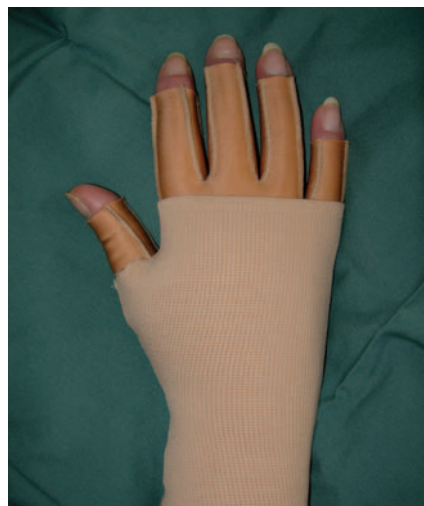

Figure 29: Standard gauntlet without a thumb (Jobst® Elvarex BSN medical, compression class 2), is combined with standard interim glove (Cicatrex interim, Thuasne(R), France)

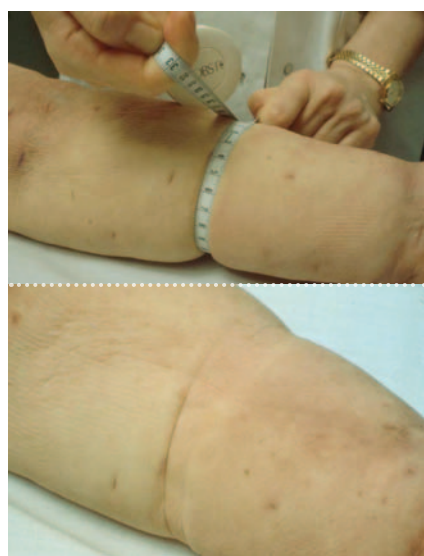

Figure 30: Measurements being taken at postoperative follow-up. Arm is still swollen at this stage. Firm measurements are taken to overcome the normal postoperative oedema. Note the indentation by the tape measure

application is therefore thoroughly described and discussed at the first clinical evaluation. If the patient has any doubts about continued CCT, she is not accepted for treatment. After initiating compression therapy, the custom-made garment is taken in at each visit using a sewing machine, to compensate for reduced elasticity and reduced arm volume. This is important during the first three months when the most notable changes in volume occur. At the one- and three-month visits the arm is measured for new custom-made garments. *Figure 32* shows an online order form for the different garments. This form is useful as it has all the values, enabling you to see what you are aiming for and what you have ordered before. Measurements are pulled tightly since it is the postoperative oedema that you want to reduce (*Figure 30*). This procedure is repeated at six, (nine) and 12 months. If complete reduction has been achieved at six months, the nine-month control may be omitted. If this is the case, remember to prescribe

whole arm (60 × 60cm, Cover-Dri, www.attends.co.uk). The arm is kept at heart level on a large pillow. The compress is changed when needed.

The following day, a standard gauntlet (a glove without fingers with a thumb), where the thumb has been cut off (Jobst® Elvarex BSN medical, compression class 2) is put over the interim glove (*Figure 29*). If the gauntlet is put on straight after surgery, it can exert too much pressure on the hand when the patient is still unable to move the fingers after the anaesthesia. Operating time is, on average, two hours. An isoxazolyl penicillin or a cephalosporin is given intravenously for the first 24 hours, and then in tablet form until incisions have healed, about 10–14 days after surgery.

Postoperative care

The arm is held raised by the patient herself during hospital stay. Garments are removed two days postoperatively so that the patient can take a shower and measurements are compared with the normal arm (*Figure 30*). There is no bruising because the compression is put on before releasing the tourniquet. The tumescence solution and any blood leak out through the small incisions. Water-soluble ointment that does not destroy the garment is applied. Then a new Elasto-Gel (Southwest Technologies, USA) is put on the elbow. The other set of garments is put on and the used set is washed and dried. This is repeated by the patient herself after another two days before discharge. The standard glove and gauntlet is usually changed to the made-to-measure glove at the end of the stay.

The patient alternates between the two sets of garments (two sleeves and two gloves) during the first two postoperative weeks, changing them daily or every other day so that a clean set is always put on after showering and lubricating the arm. After the two-week control, the garments are changed every day after being washed. Washing 'activates' the garment by increasing the compression due to shrinkage (*Figure 31*). It also removes perspired salt that can cause dry and irritated skin. During the subsequent course, this rigorous compression regime, referred to as controlled compression therapy (CCT), is maintained exactly as described below.

Controlled compression therapy (CCT)

A prerequisite to maintaining the effect of liposuction, and, for that matter, conservative treatment, is the continuous use of a compression garment (Brorson and Svensson, 1998). Compression therapy is crucial, and its

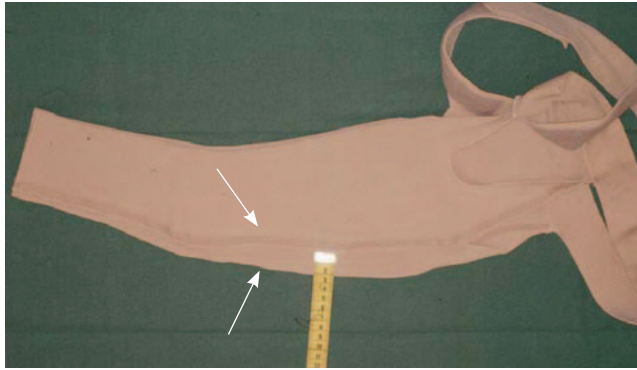


Figure 31: Two identical compression garments on top of each other, showing the effect of washing on the garment. Note that the circumference has decreased 4 cm after washing

Order Orderstock

	Vänster	Höger
Sida		X

	Vänster	Höger
IGIH	12	
Band	105	
cG	36,5	
cF	31	
cE	27	
cD	24	
cC	18,5	
ICG	45	
ICF	33	
ICE	23	
ICD	13	

a

Order Orderstock

	Vänster	Höger
Sida		X

	Vänster	Höger
CA	17,5	
cB	18,5	
cE1	21	
cC	16,5	
IAB	2,5	
IAC	8,5	
IAC1	15	
X	7,5	
Z	11	
Z-X	3	
Z (1)	6,8	
X (1)	7,5	
Z-X (1)	3	
Z (2)	6,8	
X (2)	7,5	
Z-X (2)	3,5	
Z (3)	6	
X (3)	6,7	
Z-X (3)	3,5	
Z (4)	5,7	
X (4)	6,3	
Z-X (4)	2,5	

b

Figures 32a and b: Online ordering forms for compression garments

garments for six months, which normally means double the amount that would be needed for three months. It is important, however, to take in the garment repeatedly to compensate for wear and tear. This may require additional visits in some instances, although the patient can often make such adjustments herself. When the excess volume has decreased as much as possible, i.e. no pitting is seen, and a steady state has been achieved, new garments can be prescribed using the latest measurements. In this way, the garments are renewed three or four times during the first year. A checkup should be done at one and a half years for compliance and volume measurements. If everything is stable at two years, a once-yearly visit is enough. Two sets of sleeve and glove garments are always at the patient's disposal; one being worn while the other is washed. Thus, a garment is worn permanently, and treatment is interrupted only briefly when showering and, possibly, for formal social occasions. The patient is informed about the importance of hygiene and skin care, as all patients with lymphoedema are susceptible to infections and keeping the skin clean and soft is a prophylactic measure (Brorson and Svensson 1997a, 1998).

The life span of two garments worn alternately is usually four to six months. After complete reduction has been achieved, the patient is seen once a year when new garments are prescribed for the coming year, usually four garments and four gloves (or four gauntlets). In active patients, six to eight garments and the same amount of gauntlets/gloves a year are needed. Patients without preoperative swelling of the hand can usually stop using the glove/gauntlet after 6–12 months postoperatively.

For legs, the authors' team often uses up to two to three compression garments on top of each other, depending on what is needed to keep pitting away. A typical example is Jobst Bellavar® compression class 2, Elvarex® compression class 3, Forte and Elvarex® compression class 2 (BSN medical). The latter can be a leg-length or a below-the-knee garment. Thus, such a patient needs two sets of 2–3 garments. One set is worn while the other is washed. Depending on the age and activity of the patient, two sets can last for 2–4 months. Thus, patients should be prescribed garments 3–6 times during the first year. After complete reduction has been achieved, the patient is seen once a year when all new garments are prescribed for the coming year.

Controlled compression therapy can also be used to effectively treat a pitting oedema as an alternative to complete decongestive therapy (CDT), which, in

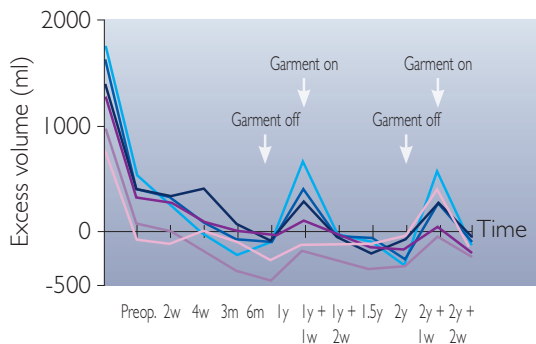


Figure 33: Removing the compression garment leads to accumulation of lymph. Putting it on again, reverses the situation (Brorson and Svensson, 1998)

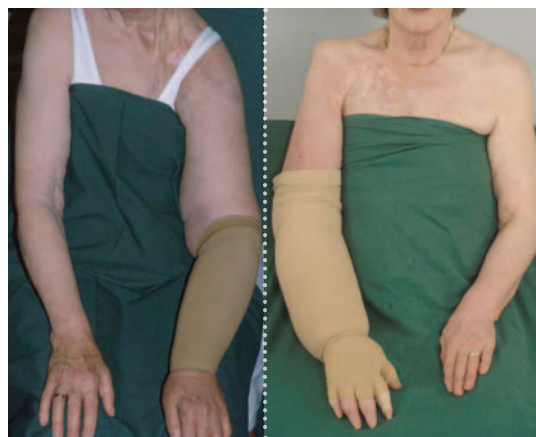

Figure 34: Ineffective and poorly-fitting compression garment

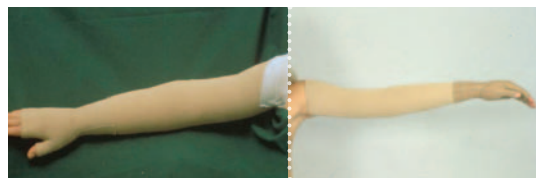


Figure 35: Effective, tailor-made compression garment that fits perfectly

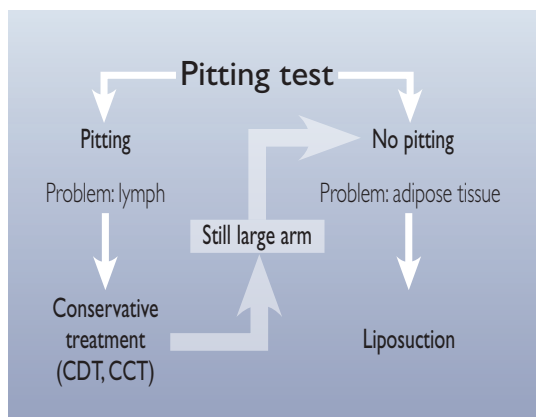


Figure 36: The pitting test decides if conservative therapy or liposuction is indicated to reduce excess volume

contrast to CCT, comprises daily interventions (Brorson and Svensson, 1998). Controlled compression therapy is simple, economic and efficient.

Every chain has its weakest link and the weakest link in oedema treatment is the compression garment. If oedema increases after the operation, it is due to the compression garment being ineffective or decreased patient compliance. Compression is crucial to maintain the effect of liposuction.

Increasing compression

Compression can be increased when pitting is still present. Increased compression can be achieved by:

- decreasing the circumferential measurements when ordering compression garments
- increasing the compression class
- using several compression garments (multilayer)
- increasing the amount of garments prescribed at the same time, or
- taking in existing garments.

Class 2 is often used, but some patients need class 3. With legs, class 3 or 4 can be used. Alternatively, several layers can be placed on top of each other.

Removal of compression garments

Figure 33 shows the pre- and postoperative excess volumes in six patients. To see what would happen if compression garments were not worn, the authors removed them from six patients and after one week the excess volume had increased in all the patients. The garments were put back on and, after another week, the excess volume had again lessened. A year later the experiment was repeated because the authors thought that a possible postoperative scar formation within the tissue might stabilise the situation. Again, the excess volume returned on removal of the garments and disappeared when the garments were put back on (Brorson and Svensson, 1998).

Thus, the way to control oedema is compression, compression, compression....

Correct compression must also be worn. Figure 34 (right) shows a garment that is too large and has slithered down, strangulating the wrist. Figure 34 (left) shows a compression garment that is thought to be for the lower leg, but the patient has been using it herself on the arm by cutting off the foot. This will have no effect whatsoever. Figure 35 is an example of how a compression garment should fit: custom-made and fitting perfectly.

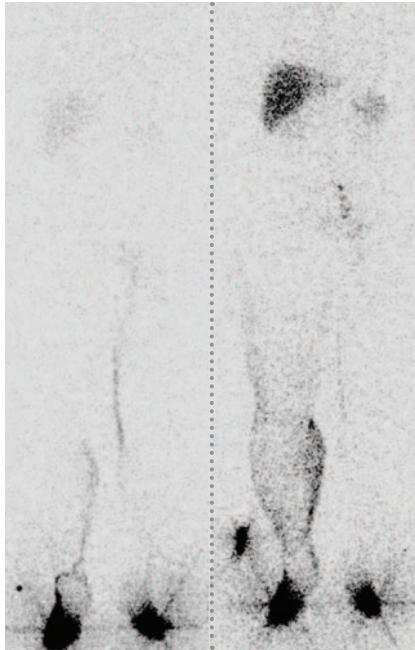


Figure 37: Lymphoscintigraphy. Typical dermal backflow in the right leg, while the left leg shows normal lymph transport

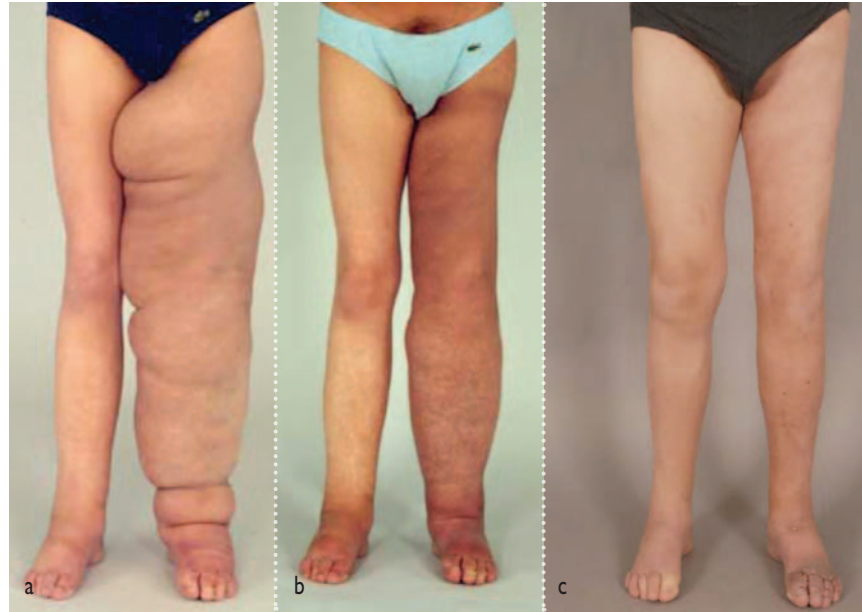

Figure 38a: A man with congenital lymphoedema that worsened after surgical removal of a seminoma and postoperative radiotherapy. Preoperative excess volume was 14.300 ml. Figure 38b: After six months, 10 litres of fluid had been removed. Figure 38c: Eight years after CCT and liposuction no recurrence can be seen

Liposuction is not the first choice of treatment and should not be performed without training. It is a lifetime commitment both for the surgeon, who should be well trained, and for the patient. Liposuction *per se* is not the solution — it is the start and should then be continued with compression garments for life, just like after CDT.

The key to success is the information provided to the patients. A mental contract with them facilitates compliance. Equally, if a patient cannot be supplied with a sufficient number of garments, liposuction should not be performed.

As said, the pitting test acts as a simple means of classification (Figure 36). Where there is pitting, there is still oedema; if there is no pitting, lymphoedema has turned into adipose tissue (Box 1). If there is still pitting, the patient should be treated with conservative therapy until no, or minimal pitting is seen. Then the decision can be made as to whether it is sufficient for the patient. If the patient wants further reduction, liposuction is an option.

Many lymph therapists regard it as normal for patients to come back regularly for maintenance therapy. Patients are pleased with their initial treatment, but then return to the therapist because their arm has swollen again, about six months later. The whole process with CDT is repeated. After another six months the arm is swollen again, new treatment with CDT, and so on.... This begs the question as to why the therapist did not analyse why and when the arm had become swollen again. If a therapist had seen the patient every two months during the first year after treatment, measuring both arms and seeing when the swelling started to come back, new garments could have been ordered. Thus, after one year you would know exactly how many garments the patient needed, and the correct number could be ordered for the following year. A check-up should be done at one and a half years for compliance and volume measurements. If everything is stable at two years, a once-yearly visit is enough. In the long run this will save time, money and unnecessary visits.

Box 1: Inclusion criteria for liposuction

- No pitting
- Continuous compression with garments
- Arm swelling around 1000 ml, can be as low as 500 ml but also the patient's BMI should be considered
- No active breast cancer
- No effect of conservative therapy
- No wounds

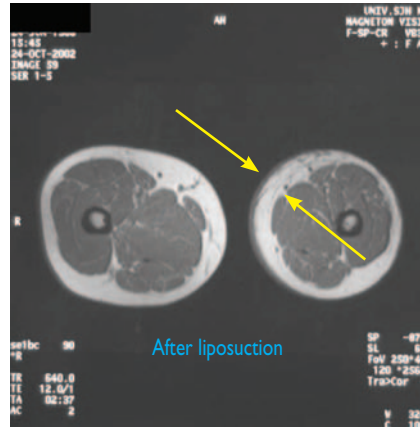
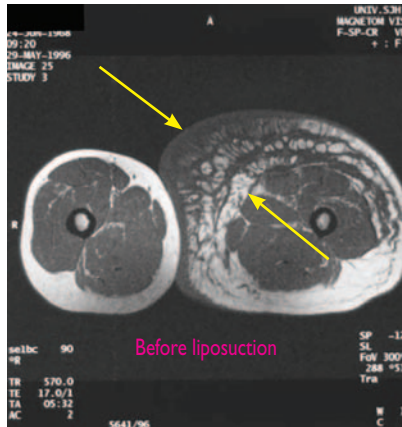


Figure 39: MRI a) Shows the swollen left leg before treatment. b) Result after CCT and liposuction

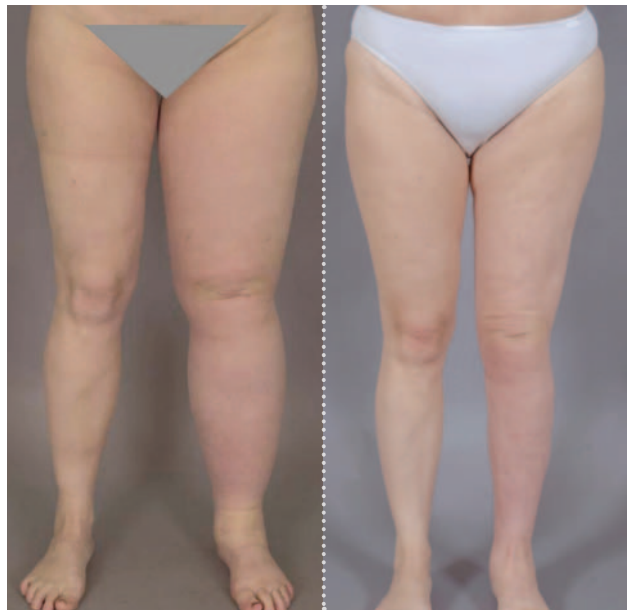

Figure 40: Typical example of primary lymphoedema. Left-hand figure shows preoperative limb with an excess volume of 4.490 ml; right-hand figure two years postoperatively

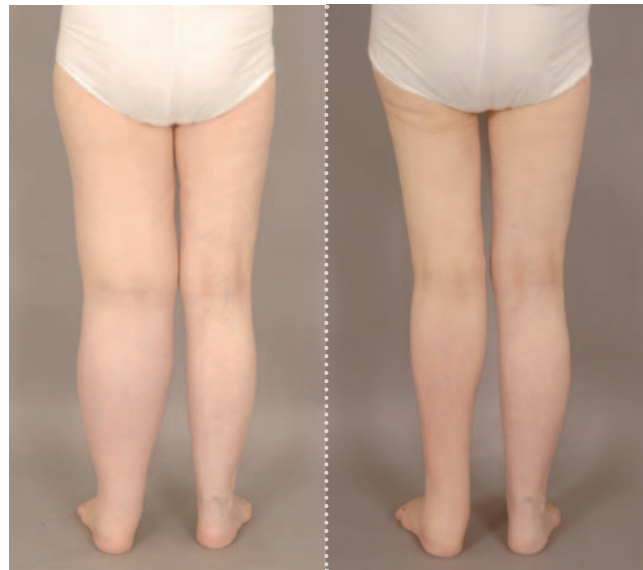

Figure 42: 73-year-old woman who has had a primary lymphoedema since she was 50 years old. Preoperative excess volume was 5.790 ml (left-hand figure), and six months after surgery where there is a slight overcorrection (right-hand figure)

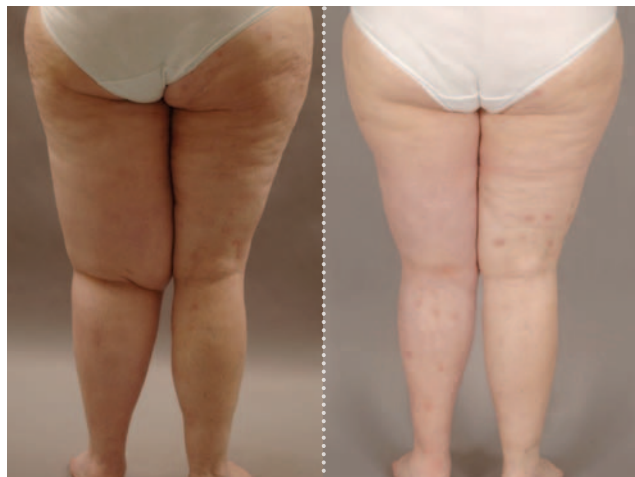

Figure 41: Typical example of secondary lymphoedema. Left-hand figure shows preoperative limb with an excess volume of 4.565 ml; right-hand figure one year postoperatively

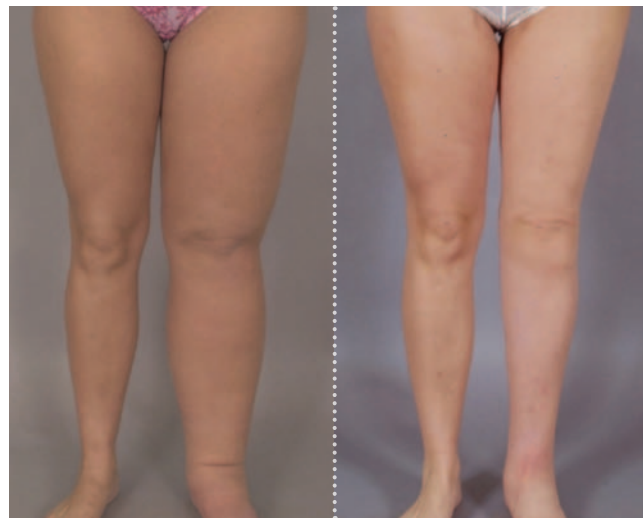

Figure 43. Preoperative excess volume 6630 ml (left-hand figure). Postoperative result after two years where excess volume is 30 ml (right-hand figure)

Leg lymphoedema

Most patients with lymphoedema show a positive Stemmer's sign, but a negative Stemmer's sign does not exclude lymphoedema.

Figure 37 shows a typical lymphoscintigraphy of a lower leg lymphoedema. The injection can be seen on the feet and the uptake in the liver. After four hours there was a dermal backflow in the right leg and no uptake in the lymph glands in the groin. The left leg shows normal lymphatics and lymph nodal uptake in the groin.

Figure 38a shows a man with congenital lymphoedema that worsened after surgical removal of a seminoma and postoperative radiotherapy. Preoperative excess volume was 14.310ml. A garment was applied to this patient, which was taken in after the size reduced as a result of CCT. In six months, 10 litres of fluid had been removed (*Figure 38b*). Eight years after CCT and liposuction, no recurrence could be seen (*Figure 38c*). Where there is no pitting but still excess volume, it is adipose tissue. The MRI scan in *Figure 39* shows the thickness of subcutaneous space before and after liposuction and CCT in this patient (Brorson et al, 2008).

Figures 40–43 show examples of primary and secondary lymphoedemas before and after surgery.

Figure 44 shows a male patient with class III leg-long flat-knit compression, and another round-knit class II compression garment and below-the-knee class II flat-knit compression garment on the right leg. He later developed lymphoedema in the left leg, where he wore class III leg-long flat-knit compression and another leg-long round-knit class 2. For one year the authors ordered six garments of each at the same time. The patient numbered the garments from one to six, so that, for example, he wore those with number three for 24 hours. These were then removed when he took a shower and lubricated the skin with a water soluble ointment. He would then put on the next set of garments marked with number four; and so on. The used set was washed. By doing this, he always knew which set of garments should be put on. In total he needed 30 garments a year, demonstrating the importance of being able to afford garments so that the lymphoedema does not recur.

Figures 45 and 46 show how a patient found that she could use bandages for hernias to treat a localised oedema in the genital region. The bandage was modified with a piece of an elastic roll that was secured in the front with velcro.

Conclusion

Liposuction is an effective treatment on chronic large lymphoedema not responding to conservative regimens.

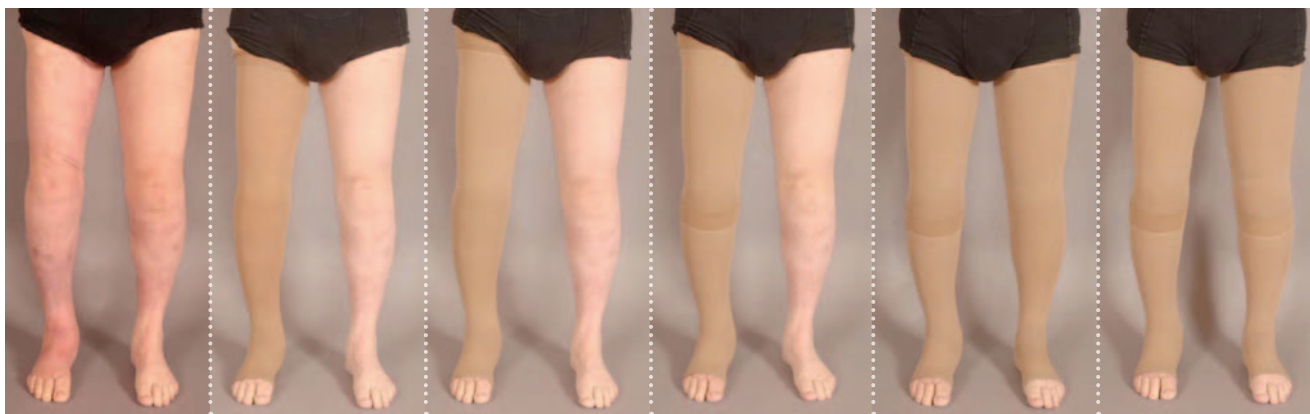


Figure 44: This patient needs the following compression: Right leg: Elvarex 3 Forte (leg-long), Bellevar 2 (leg-long), Elvarex 2 (below-the-knee). Left leg: Elvarex 3 Forte (leg-long), Bellevar 2 (below-the-knee). For one year he needs six of each. All garments for one year are ordered at the same time, in total 30 garments

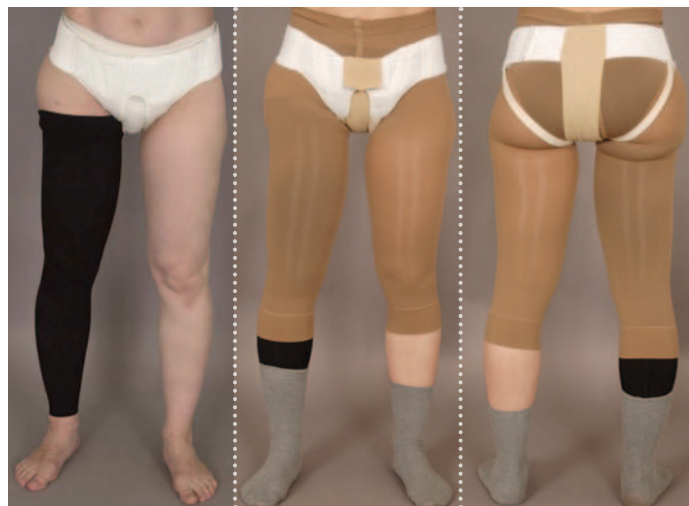

Figure 45: This patient has obtained excellent compression by the use of a hernia garment supplemented with a piece of elastic roll (Dauer) that has been sewn together at the back and fastened by velcro in the front



Figure 46: Hernia garment

Providing that the compression garments are used all the time, even after 14 years there is no recurrence. Excess adipose tissue can be removed by liposuction, but not by CDT, compression pumping or microsurgery.

In Sweden the costs for treating lymphoedema are:

- 8,300 euros for an arm; 11,000 euros for a leg
- garments cost 120 euros a pair
- gauntlets cost 180 euros a pair
- patient pays 30 euros for each outpatient visit.

The patient pays nothing for hospitalisation (4–7 days), surgery or compression garments, as it is done within the Swedish health care system. Since 1998 the authors' clinic has been approved as a clinic for the treatment of post-mastectomy and lymphoedema with liposuction by the Swedish National Board of Health and Welfare.

To conclude, it is important to be open-minded with regard to liposuction. In the authors' opinion, if they had read all the 'dos and donts' before starting this novel treatment, they would never have obtained the results that they have achieved.

All figures are reproduced by kind permission of Håkan Brorson

References

- Bagheri S, Ohlin K, Olsson G, Brorson H (2005) Tissue tonometry before and after liposuction of arm lymphedema following breast cancer. *Lymphat Res Biol* **3**: 66–80
- Borley NR, Mortensen NJ, Jewell DP, Warren BF (2000) The relationship between inflammatory and serosal connective tissue changes in ileal Crohn's disease: evidence for a possible causative link. *J Pathol* **190**(2): 196–202
- Brorson H, Svensson H (1997a) Complete reduction of lymphoedema of the arm by liposuction after breast cancer. *Scand J Plast Reconstr Surg Hand Surg* **31**(2): 137–43
- Brorson H, Svensson H (1997b) Skin blood flow of the lymphedematous arm before and after liposuction. *Lymphology* **30**: 165–72
- Brorson H (1998) *Liposuction and Controlled Compression Therapy of Arm Lymphedema Following Breast Cancer*. Thesis. Studentlitteratur; Lund, Sweden

- Brorson H, Svensson H (1998) Liposuction combined with controlled compression therapy reduces arm lymphedema more effectively than controlled compression therapy alone. *Plast Reconstr Surg* **102**: 1058–67
- Brorson H, Svensson H, Norrgren K, Thorsson O (1998) Liposuction reduces arm lymphedema without significantly altering the already impaired lymph transport. *Lymphology* **31**(4): 156–72
- Brorson H, Åberg M, Svensson H (2004) Chronic lymphedema and adipocyte proliferation: Clinical therapeutic implications. *Lymphology* **37**(Suppl): 153–5
- Brorson H, Ohlin K, Olsson G, Långström G, Wiklund I, Svensson H (2006a) Quality of life after liposuction and conservative treatment of arm lymphedema. *Lymphology* **39**: 8–25
- Brorson H, Ohlin K, Olsson G, Nilsson M (2006b) Adipose tissue dominates chronic arm lymphedema following breast cancer: an analysis using volume rendered CT images. *Lymphat Res Biol* **4**(4): 199–210
- Brorson H, Ohlin H, Svensson B, Svensson H (2008) Controlled compression therapy and liposuction treatment for lower extremity lymphedema. *Lymphology* **41**: 52–63
- Brorson H, Ohlin K, Olsson G, Karlsson MK (2009) Breast cancer-related chronic arm lymphedema is associated with excess adipose and muscle tissue. *Lymphat Res Biol* **7**: 3–10
- Clayton DN, Clayton JN, Lindley TS, Clayton JL (1989) Large volume lipoplasty. *Clin Plast Surg* **16**(2): 305–12
- Courtiss EH, Choucair RJ, Donelan MB (1992) Large-volume suction lipectomy: an analysis of 108 patients. *Plast Reconstr Surg* **89**(6): 1068–79; discussion 1080–2
- Goodpasture JC, Bunkis J (1986) Quantitative analysis of blood and fat in suction lipectomy aspirates. *Plast Reconstr Surg* **78**(6): 765–72
- Harvey NL, Srinivasan RS, Dillard ME, Johnson NC, Witte MH, Boyd K, Sleeman MW, Oliver G (2005) Lymphatic vascular defects promoted by Prox1 haploinsufficiency cause adult-onset obesity. *Nat Genet* **37**(10): 1072–81
- Illouz YG (1983) Body contouring by lipolysis: a 5-year experience with over 3000 cases. *Plast Reconstr Surg* **72**(5): 591–7
- Jones B, Fishman EK, Hamilton SR, Rubesin SE, Bayless TM, Cameron JC, et al (1986) Submucosal accumulation of fat in inflammatory bowel disease: CT/pathologic correlation. *Int J Comput Assist Tomogr* **10**: 759–63
- Klein JA (1993) Tumescent technique for local anesthesia improves safety in large-volume liposuction. *Plast Reconstr Surg* **92**(6): 1085–100
- Klein JA (1987) The tumescent technique for lipo-suction surgery. *Am J Cosmetic Surg* **4**(4): 263–7
- Lantz M, Vondrichova T, Parikh H, Frenander C, Ridderstrale M, Asman P, et al (2005) Overexpression of immediate early genes in active Graves' ophthalmopathy. *J Clin Endocrinol Metab* **90**(8): 4784–91
- Rohrich RJ, Mathes SJ (1990) Suction lipectomy. In: MJ Jurkiewicz, TJ Krizek, SJ Mathes and S Ariyan, eds. *Plastic Surgery: Principles and Practice*. Mosby, St. Louis: 1553
- Samdal F, Amland PF, Bugge JF (1995) Blood loss during suction-assisted lipectomy with large volumes of dilute adrenaline. *Scand J Plast Reconstr Surg Hand Surg* **29**(2): 161–5
- Schneider M, Conway EM, Carmeliet P (2005) Lymph makes you fat. *Nat Genet* **37**(10): 1023–4
- Sheehan AL, Warren BF, Gear MW, Shepherd NA (1992) Fat-wrapping in Crohn's disease: pathological basis and relevance to surgical practice. *Br J Surg* **79**(9): 955–8
- Wojnikow S, Malm J, Brorson H (2007) Use of a tourniquet with and without adrenaline reduces blood loss during liposuction for lymphoedema of the arm. *Scand J Plast Reconstr Surg Hand Surg* **41**: 243–9

Further reading

- Brorson H (2003) Liposuction in arm lymphedema treatment. *Scand J Surg* **92**: 287–95
- Brorson H (2004) Liposuction and the consensus document: response to Professor M Foldi's remarks at the 19th International Congress of Lymphology. *Lymphology* **37**(4): 174
- Brorson H (2004) Adipose tissue in lymphedema: the ignorance of adipose tissue in lymphedema. *Lymphology* **37**(4): 135–7
- Brorson H, Ohlin H, Svensson B (2008) The facts about liposuction as a treatment for lymphoedema. *J Lymphoedema* **3**(1): 38–47
- Warren AG, Brorson H, Borud LJ, Slavin SA (2007) Lymphedema: a comprehensive review. *Ann Plast Surg* **59**: 464–72